

LABORATORY

5

Lungworms, *Strongyloides*, Spirurids, and Filarids**Introduction:**

In this lab we have placed several small (but very important) groups of nematodes. With the exception of the *Strongyloides* spp., and a few spirurids, these worms live outside the GI tract. The lungworms, as the name indicates, live in the lungs (parenchyma or bronchi/trachea) of their host. Most are members of the Superfamily Metastrongyloidea and their L1 have a "kink" in the tail. However, *Dictyocaulus* spp. are in the family Trichostrongyloidea and their L1 have a straight tail. The genus *Strongyloides* contains many species that are important parasites of neonatal animals. The small parasitic adult is a parthenogenic female that lives in the crypts of the small intestine. All species of this genus have one or more free-living generations. The Spirurids and Filarids are nematode parasites that live in the tissues or vasculature of their hosts (with exception of some spirurids that live in the stomach). The Spirurids lay larvated eggs, while the Filarids females are viviparous and "give birth" to actively motile embryos called microfilariae. The Filarid life cycles involve an intermediate host (generally a blood sucking arthropod) and, as a rule, the Spirurid life cycle involves an arthropod intermediate host.

Objective:

Both *Oslerus* spp. and *Strongyloides stercoralis* infections are diagnosed by finding the larvae (L1s), rather than eggs, in **fresh** feces of dogs. Hookworm larvae may also be present in **old**, non-refrigerated feces (≥ 24 hours old), and, therefore, you may need to distinguish these 3 kinds of larvae in practice. The objectives of today's laboratory are to learn the diagnostic stages of lungworms and *Strongyloides stercoralis* from dogs, as well as, to learn to recognize the larvae of *Aelurostrongylus* of cats and the eggs of the other *Strongyloides* spp. that parasitize a great diversity of hosts, both wild and domestic. The adults of these nematodes, when found at necropsy, can be distinguished on the basis of size, shape, and their location within the host.

The filariid worms produce microfilariae that accumulate in the skin or blood awaiting ingestion by an arthropod vector. Parasitologic diagnosis is made by finding these microfilariae either in blood or in skin snips. In today's lab you will learn how to recognize the microfilariae of *Dirofilaria immitis* in the blood of the dog. You will also learn several techniques for concentrating these microfilariae in order to make this diagnostic technique more sensitive. Finally you will have the opportunity to run several configurations of the antigen-capture serologic assay for adult heartworm infection.

Checklist of Objectives:

Be able to identify the following:

- The typical lungworm L1 (“kinked” tail) and be able to identify to species (by host).
- Dictyocaulus* spp. L1 from cattle (larva with straight tail in **fresh** feces).
- The eggs and L1 of *Strongyloides* spp.
- Distinguish between and recognize the L1 of *Strongyloides stercoralis*, *Ancylostoma* sp., and *Oslerus (Filaroides)* sp. from the feces of dogs and *Aelurostrongylus* sp. from cat feces.
- Adult *Dirofilaria immitis* (by size and location in host).
- Adult *Spirocerca lupi* (by size and location in host).
- microfilaria (the pre-L1 stage of filariids).
- a spiruid egg (all similar to *S. lupi* eggs).

Be able to do (and explain the theory behind) the following techniques:

- The Knott concentration technique.
- The Filtration technique.
- An assay for heartworm antigen.

At the Bench

1.) *Oslerus (Filaroides) osleri* - these lungworm larvae are found in fresh dog feces.

One slide on each bench:

First-stage (L1) larvae (pg. 29, Foreyt), esophagus is longer than the distinctly bulbed rhabditiform esophagus (i.e. less distinctly bulbed) of the first-stage *Strongyloides* larvae. “Strongyliform” esophagus, no mouth tube, and irregular, digitiform or “kinked” tail (see Diagram 1 in Appendix 1). This L1 is the infectious stage of this parasite.

2.) *Aelurostrongylus abstrusus* - these lungworm larvae are found in fresh cat feces.

One slide on each bench:

Note the kinked (S-shaped) tail (Pg. 57, Foreyt). Similar to *Oslerus osleri* L1, but found in cat feces. The L1 is infectious for the intermediate host (a snail or slug) but must develop to the L3 before it is infectious to the cat (or paratenic host). This lungworm is most often seen in cats that hunt and eat mice (a paratenic host), thus it is commonly seen in stray and “barn” cats.

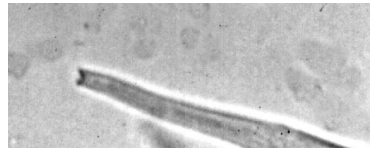3.) *Strongyloides stercoralis* - 1st stage larvae are found in fresh feces. (L1, rather than eggs, pass in feces. In other species of *Strongyloides* a larvated egg is passed.) Additionally, a few precociously developed infective larvae (L3) may be present in fresh feces of *S. stercoralis* infected animals.

Living L1s and L3s were obtained by using a Baermann apparatus and fresh feces or 7-day-old fecal-charcoal cultures, respectively. (**Remember:** L3s, but not L1s, are infectious for humans!!).

- A. Tube on center bench - *Strongyloides* first-stage larvae from canine feces. Size is between 280 μ and 310 μ in length, rhabditiform esophagus, **no** mouth tube, simple conical tail, and **large** genital rudiment. (Pg. 25 in Foreyt, or Diagram 1 in Appendix 1).

- B. Tube on center bench - *Strongyloides* third-stage (infective) larvae, size is 525 μ to 600 μ in length, long filariform esophagus, notched tail tip (see photo below).

S. stercoralis L3 will have a long (about 40 to 50% the length of the worm) straight esophagus and a notch at the end of the tail, whereas *A. caninum* larvae have a straight tail and short esophagus. **Note:** It is sometimes useful to culture *Strongyloides* larvae to the L3 stage for diagnostic purposes. Because multiplication occurs during the heterogonic cycle (free-living cycle) a sample with too few larvae (L1) for diagnosis initially may be found to be positive for *S. stercoralis* larvae after amplification in culture. Also, you should recognize these third-stage larvae because such larvae could be present in feces of dogs with hyperinfective strongyloidiasis and may be present in "old" stools. These L3 may also be seen in tracheal washes (dogs may get a verminous pneumonia during hyperinfection). If the dog whose stool you cultured also had hookworms you would have to distinguish these L3s from those of *Strongyloides*.



Tail of *S. stercoralis* L3. Note the notch in the end of the tail.

4) Finding *Dirofilaria immitis* microfilariae in blood - These long-lived embryos are found in the peripheral blood of heartworm infected dogs, wild canids and, rarely, felids including domestic cats (Fig 3a).

A.) Examine SSB slide #33 for microfilariae. With the advent of the antigen tests for detection of heartworm very few veterinarians still examine blood specifically for microfilariae, thus the discovery of a microfilaria on a blood smear made for other reasons is sometimes the first indication that the dog may have heartworm. These are giemsa stained blood smears. The RBC will appear red and the WBC and microfilariae (see Fig. 3a) will appear blue.

Samples of diluted blood from a *D. immitis* infected dog are provided for you on the center bench for the next 3 tests. This blood is provided through educational grant from:



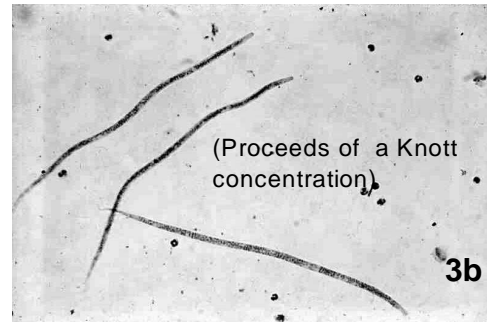
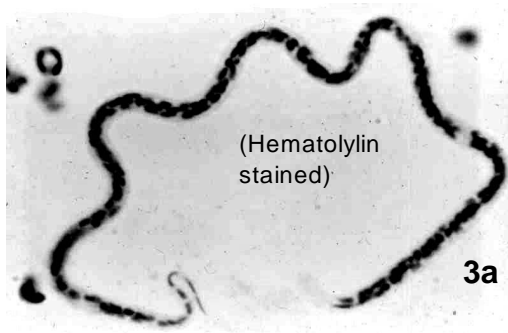
Resuspend the contents of one of these tubes and perform the following 3 observations:

B.) Make a direct mount (one drop of blood on a slide with a cover slip). Observe under the microscope for movement of microfilariae.

C.) Perform the modified Knott technique as outlined in Appendix 2. (**Note:** because this blood is dilute, you will not see a pellet of buffy coat cells as large as would be expected from centrifugation of a whole blood lysate.)

D.) Perform the filtration technique as outlined in Appendix 2.

Note: Novice diagnosticians commonly mistake artifacts such as dust, cotton fibers or strands of fibrin for microfilariae. Microfilariae of *D. immitis* are quite uniform in size and shape measuring approximately 310 μm in length with sharply pointed tails and blunt (with a slight taper) anterior ends (Fig. 3b).

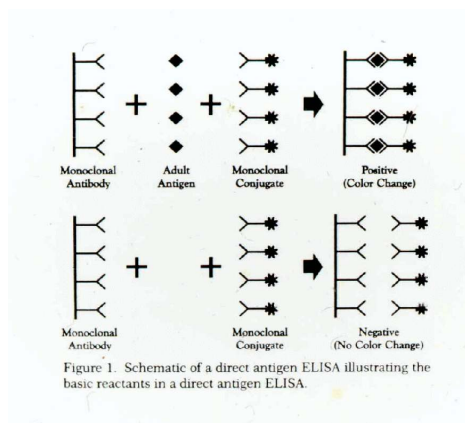


QUESTION: What are the relative advantages and disadvantages of the four techniques for detecting blood-borne microfilariae? (See an instructor or the Parasitology CAL web site for the answers.)

2) **Serodiagnosis** – Over the past two decades, serological methods for detection of *Dirofilaria immitis* infection have been developed. These provide quick, accurate and, sometimes, semi-quantitative methods of diagnosing infection with adult heartworms without microscopic examination of blood. These methods are regarded as the primary screening tests for heartworm diagnosis. They are also valuable for diagnosing occult heartworm infection in which adult heartworms and possibly heartworm disease are present, but no circulating microfilariae are detected. The most recent commercial versions of these involve detection of circulating antigen originating from the adult female worm by the general mechanism shown in Figure 2. Representatives of these commercial tests are provided for you to run on the canine sera provided. Details of this exercise will be given in the introduction to lab.

Figure 2

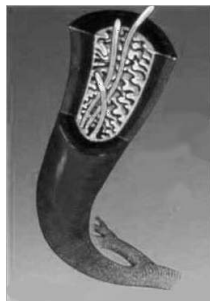How a direct antigen ELISA works.



QUESTION: Current serodiagnostic methods for feline heartworm are based on detection of circulating anti-heartworm antibodies rather than antigen from adult female worms. What is the reason for this difference? (See an instructor or the Parasitology CAL web site for the answers.)

3) Adult *D. immitis* in a Pulmonary Artery – **SSB #35** - Find the pulmonary artery with cross sections of adult worms. Note the villus-like projections of the arterial endothelium. (Fig. 1b)

Fig. 1b



Demonstrations

Checklist Material:

- 1.) *Muellerius capillaris* - typical lungworm L1 with a kinked tail, but also posses a “subterminal spine” at the base of the tail. Very common in goats in our area, but also sometimes seen in sheep. Generally first detected on a fecal float.
- 2.) *Dictyocaulus viviparous* - L1 from cattle feces. Note the straight tail. This lungworm is, taxonomically speaking, a trichostrongyle, not a metastrongyle. It is presented here because diagnostically it has larvae in the feces and adults in the lung and thus the diagnosis is similar to that of the metastrongyles. (Pg. 89, Foreyt) Generally detected on a fecal float. *D. arnfieldi* is a related species that is found in donkeys but it will infect horses, however, they rarely become patent, thus L1 are rarely seen in horse feces.
- 3.) *Aelurostrongylus abstrusus* . - these lungworm larvae are found in fresh cat feces. Note the kinked (S-shaped) tail, with a small finger like projection (a “subterminal spine”) at the base of the tail, similar to *Muellerius capillaris* (Pg. 57, Foreyt). Generally first seen on a fecal float.
- 4.) *Oslerus (Filaroides) osleri* - these lungworm larvae are found in fresh dog feces. Note the kinked (S-shaped) tail (Pg. 57, Foreyt). These larvae may be recovered from the feces either in a ZnSO₄ centrifugational float or by the Baermann technique. They may also be found in the sputum if the animal is coughing. (See diagram pg 5.)
- 5.) Hookworm L1. While the L1 is not normally the diagnostic stage of the hookworms of dogs and cats, the hookworm egg will rapidly develop at summer temperatures and may hatch within a day of the feces leaving the host. Thus if the fecal sample wasn't collected fresh and kept cool, you may see these larvae in it. Thus, you should know how to determine if the L1 you find on a fecal examination are hookworm or belong to some other parasitic or free living nematode. The only L1s of a nematode parasite that you will find in fresh cat feces is that of *Aelurostrongylus abstrusus* and it will have a kinked tail with a subterminal spine. Any L1 in cat feces with a straight tail is suspect (get a fresh fecal sample!). In dogs, *S. stercoralis* also has a straight tail, so you must check for the presence of a genital primordium (*S. stercoralis*) or a mouth tube (*A. caninum*). (See diagram pg 5.)
- 6.) *Strongyloides stercoralis* - The L1 of this nematode can be found in the fresh feces of dogs, and primates. These L1 have a straight tail and a large genital primordium (see pg. 25 in Foreyt). The genital primordium is an oval group of cells located between the body wall and the intestine, and is located about halfway down the worm. (See diagram pg 5.)
- 7.) *Strongyloides* spp.- eggs. These eggs are smaller (about half the size) than strongyle eggs and typically contain a larva when freshly passed in feces. Size = 40-60 μm X 20-25 μm. (See pg. 83 in Foreyt). *S. papillosus* is found in ruminants, *S. ransomi* is found in pigs and *S. westeri* is found in horses. *Strongyloides* spp. are most commonly seen in younger animals (neonates).
- 8.) *Dirofilaria immitis* - “Heartworm” - Adults - As adults these nematodes live in the pulmonary arteries of dogs, cats, ferrets and seals. Size, shape and location in the pulmonary arteries and right heart at necropsy are sufficient to identify these nematodes. (Fig. 1a)

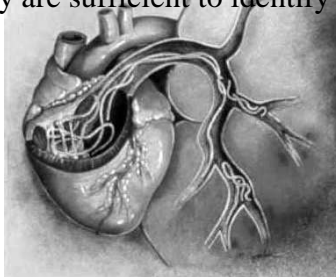


Fig. 1a.

9.) *Microfilaria* - microfilariae are found in peripheral tissues, e.g. the skin or peripheral blood circulation, where they are liable to be picked up by hematophagous arthropod vectors. Parasitological diagnosis of filarial infection is by demonstration of microfilariae in blood or skin biopsies. Microfilariae can be told from other nematode larvae by the lack of a gut, they are simply a motile bag of cells (see the results of your Knott test for an example of stained microfilariae).

Onchocerca cervicalis - Observe the microfilariae migrating out of the skin biopsy provided. This illustrates the method for parasitological diagnosis of onchocercid infections. In large animals, adult onchocercid worms usually live in the large ligaments, and microfilariae migrate through the skin. *O. cervicalis*, may cause a pruritic, non-seasonal dermatitis in horses. *O. volvulus* causes onchocerciasis in humans, a leading cause of blindness in endemic areas. In the southwestern US (and elsewhere in the world, there is a species of *Onchocerca* that lives primarily in the eye of dogs.

10.) *Spirocerca lupi* - Adults - These adults were recovered from an esophageal nodule. This nematode is found in nodules in the esophageal or, less frequently, gastric lining of dogs. The size and predilection site are enough to identify this worm. Diagnosis can also be based on radiographic imaging of nodules, endoscopic examination of the esophagus (looking for the nodule which has a characteristic nipple protruding into the lumen of the esophagus or on the presence of the distinctive eggs in feces. This nematode is common in the warmer areas of the world. In the US it is found primarily in the states that border the Gulf of Mexico, but since hurricane Katrina in 2005, stray dogs from these states have been imported to our area and offered for adoption.

11.) *Spirocerca lupi* - Eggs - Note the very small size (30 - 37 μm x 11 – 15 μm) and parallel-sided appearance. When passed in the feces eggs of *S. lupi* (like all Spiruoid eggs) contain a coiled first-stage larva. Students have remarked that this combination of characters gives *S. lupi* eggs the appearance of tiny paper clips!

Other related nematodes:

Other lungworms:

A.) *Muellerius capillaris* adults are found in the parenchyma of the lungs of sheep and goats. This is a cross section of an infected lungs and cross sections of the adult worms and the inflammatory response to them may be seen.

B.) *Dictyocaulus viviparus* - adults obtained from lungs of cattle. This slender 6 cm worms live in the bronchi of cattle.

C.) *Metastrongylus apri* - These slender white worms will measure up to 58 mm in length and are found in the air passages of the lungs.

***Strongyloides*:**

A.) *Strongyloides stercoralis* adult females from a post-mortem of a heavily infected dog. Note the small size and **all** are females. The esophagus is nearly cylindrical and at least one fourth as long as the body. Parasitic females of *Strongyloides* are parthenogenetic. Therefore, males are **not** found in the small intestine along with the adult female worms.

Free-living nematodes:

A.) This slide contains various stages of free-living nematodes. Many free-living nematodes will feed on bacteria, thus they are attracted to feces. If a stool sits on the ground for any length of time before the client collects it, you may find these nematodes in it. Some hints that you are looking at free living nematodes on your fecal float: 1.) There are various stages present, including adults. 2.) The esophagus has 2 bulbs. 3.) There is a lancet in the mouth tube. Not all free living nematodes will have either #2 or #3, but no parasitic larvae have them.

The Spirurids

Nematodes of the superfamily Spiruroidea are frequently parasites of the lumen or wall of the stomach. They lay a thick walled egg that contains a larva. Most utilize an arthropod as an intermediate host.

A.) *Physaloptera* spp. - Adult - This nematode is common in the stomachs of raccoons and opossums. Dogs and cats are occasionally infected. The eggs may not float in a standard saturated salt flotation so diagnosis is usually made by identifying the adult worm after it has been vomited or seen during endoscopy. Note the body size, lack of cervical alae and presence of a “collar” at the anterior end. The most often vomited nematode by both dogs and cats is *Toxocara* spp., so be sure you can tell the difference between *Toxocara* and *Physaloptera*.

B.) *Spirocerca lupi*

This nematode is found in nodules in the esophageal or, less frequently, gastric lining of dogs. Diagnosis is based on radiographic imaging of nodules or on presence of distinctive eggs in feces.

A. Pathology - Esophageal nodule. This gross specimen shows the worms within a nodule in the wall of the esophagus of a dog. This nodule can go on to become a sarcoma. *S. lupi* is the only cause of canine esophageal sarcomas in the USA.

B. Radiology - Esophageal nodule and vertebral changes.

C. Endoscopy - note the “nipple” like protuberance on the nodule.

C.) *Gongylonema* spp.

A. Adults - The adults of these spirurid worms are found embedded in the mucosa of the upper portion of the gastrointestinal tract of many host species. Ruminants are the preferred hosts.

B. Pathology - Note the sinous tracks in the wall of the esophagus. Before fixation, these tracks were filled with blood and were thus bright red.

The Dracunculids

These nematodes are members of the superfamily Dracunculoidea. These nematodes are generally found in the subcutaneous tissues. The only genus of medical or veterinary importance is *Dracunculus*.

A.) *Dracunculus insignis*

a. Adults - In North America, the adults of this nematode are found in the subcutaneous tissues of raccoons and, occasionally, dogs and cats. In tropical Africa, a close relative, *Dracunculus medinensis*, causes Guinea Worm disease. The female worm will cause

an ulcer to form in the skin. When the ulcer comes in contact with water the anterior end of the worm will emerge and the uterus will prolapse through the body wall or mouth of the worm. The uterus will then rupture freeing L1 into the water.

b. L1 - This is the stage that is infective to the intermediate host, *Cyclops* sp. If a tube of water is placed over the skin ulcer formed by the female worm, L1 will be discharged into the tube and can be used to diagnose the infection.

Filarids

These nematodes are members of the superfamily Filarioidea. They are long, slender, whitish nematodes without lips. They dwell in the blood or lymph vessels, body cavity or connective tissues of the vertebrate host. Fertile females are viviparous and "give birth" to actively motile vermiform (worm like) embryos called **microfilariae**. Microfilariae are in the peripheral circulation or skin and are used for parasitologic diagnosis.

A.) *Dirofilaria immitis*

Development of *Dirofilaria immitis* in its mosquito vector. *D. immitis* undergoes a required developmental sequence in a susceptible mosquito. This demonstration illustrates this sequence.

a. Females of *Aedes aegypti* feeding on blood containing microfilariae of *Dirofilaria immitis* via an artificial membrane feeding apparatus.

b. Digestive tract (Fig. 4) of a blood engorged *Ae. aegypti*.

c. Gut contents of female *Ae. aegypti* showing microfilariae of *D. immitis*.

d. Larvae of *D. immitis* from the malpighian tubules (Fig. 4) 6 days after infection.

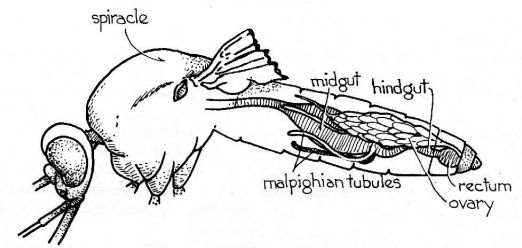


Figure 4

e. Third-stage (infective) larvae in mouthparts (labial sheath) and malpighian tubules 13 days after infection.

B.) *Dipetalonema reconditum*

This non-pathogenic filaria is found in the subcutaneous tissues of the dog and is transmitted by fleas. Its microfilariae are located in the peripheral blood and thus can confound the diagnosis of *D. immitis* infection based solely on presence of microfilariae *per se*. However, the antigen-capture serologic tests we have discussed are specific for *Dirofilaria* and will not cross react with *Dipetalonema*. Therefore, with serodiagnosis the first line of heartworm diagnosis, this confounding factor is less problematic. *Dipetalonema* infection would be on the list of differential diagnoses in the relatively rare case of a healthy, microfilaria positive dog without circulating heartworm antigen.

QUESTION: What would be another differential diagnosis in such an animal? (See an instructor or the Parasitology CAL web site for the answers.)

In such rare cases, microfilariae may be referred to a specialist for identification. The following material on identifying *Dipetalonema* microfilariae is provided for your information, but it is not listed among the objectives of this lab exercise. Differing morphological characters (see table in the appendix) and differential acid phosphatase staining patterns provide the specialist with a means of distinguishing microfilariae of *Dirofilaria* and *Dipetalonema*.

Microfilaria - This is a specimen from a Knott test. Note the differences in size and in the shape of the anterior ends especially. Also notice how the microfilaria is bent into a "U" shape, unlike the microfilaria of *D. immitis*.

C.) *Setaria equina*

Adults - These nematodes are usually harmless and live in the peritoneal and pleural cavities of horses. These are long slender worms. Their size, shape and location are sufficient basis for identification. Microfilariae would be found in the peripheral blood. These worms are transmitted by mosquitoes.

APPENDIX 1

Differential diagnosis of canine nematodiasis based on L1 larvae, the stage that typically appears in the feces in *Strongyloides* and *Oslerus (Filaroides)* infections:

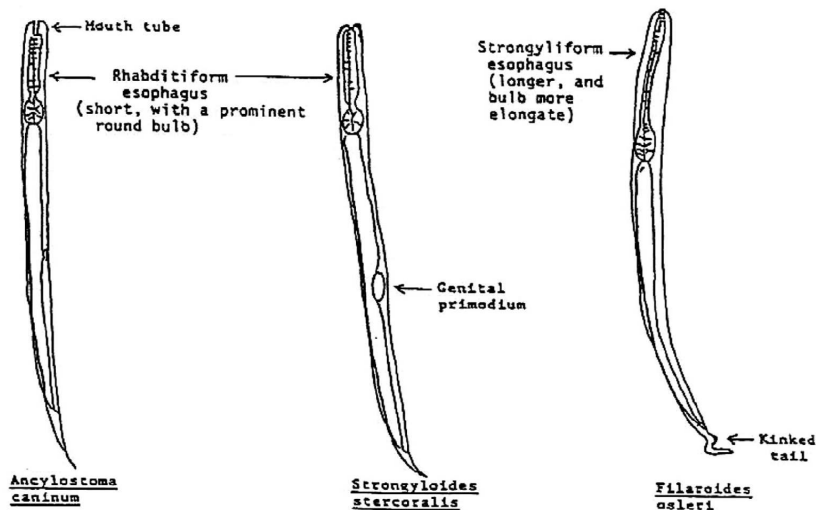
Distinguish between the larvae of the following species. These are larvae that might occur in a 24-hour-old canine fecal sample: a) *Strongyloides stercoralis* (L1) b) *Ancylostoma caninum* (L1) c) *Oslerus (Filaroides) osleri* (L1).

See the diagram below for details. The following "key" may help you identify the L1s:

- A. *Ancylostoma* spp. are found as eggs in fresh feces; if the feces are fresh and only larvae are found, eliminate hookworms from consideration. If only eggs are found eliminate *Oslerus (Filaroides)* and *Strongyloides*.
- B. If the tail of the L1 is "kinked" then the nematode is *Oslerus (Filaroides)* sp. (or *Aelurostrongylus* sp. if from a cat). If the tail is straight then go on to C.
- C. If the L1 lacks a prominent mouth tube, and has a prominent genital rudiment it is *Strongyloides stercoralis*. (You may have to examine several L1s in order to find the one in which the genital rudiment is in such a position that it is visible.)
- D. If the L1 with the straight tail has a prominent mouth tube (and no visible genital rudiment) then it is *Ancylostoma* spp. (This assumes that the feces are old.)

Diagram 1.

Primary Diagnostic Features of Nematode Larvae (L1) found in Dog Feces.



APPENDIX 2

LABORATORY METHODS FOR DIAGNOSIS OF CANINE HEARTWORM INFECTION BY THE DEMONSTRATION OF MICROFILARIAE

There are several reasons for using one of the concentration techniques in the laboratory examination of dog blood for microfilariae. Probably the main reason for using a concentration method vs. the direct smear is that more than 25% of the positive cases may be missed if the direct smear is the only method used. Secondly, a concentration method that kills the microfilariae allows easy differentiation between *Dirofilaria immitis* and *Dipetalonema reconditum*.

The two acceptable concentration methods most commonly employed in practitioners' laboratories are:

A.Modified Knott Method (Knott J. A method for making microfilarial surveys on day blood. *Trans Roy Soc Trop Med Hyg* 1939;33:191-196.)

- 1.Add 1 ml freshly-drawn blood to 9 ml 2% formalin (aqueous) in a centrifuge tube.
- 2.Mix well to lyse red blood cells.
- 3.Centrifuge for 5 minutes at 1500 rpm.
- 4.Pour off supernatant fluid. Note: Invert the tube completely when decanting the supernatant. Remember, the blood sample you are using is dilute so you won't see a large pellet.
- 5.Add a drop of 0.1% aqueous methylene blue. (Adjust the amount to suit yourself; it stains the microfilariae blue and makes them much easier to see.) Then stir or mix up the sediment in the bottom of the tube.
- 6.Mix again and place a drop of the stained mixture on a microscope slide and add a cover slip.
7. Examine under a microscope.

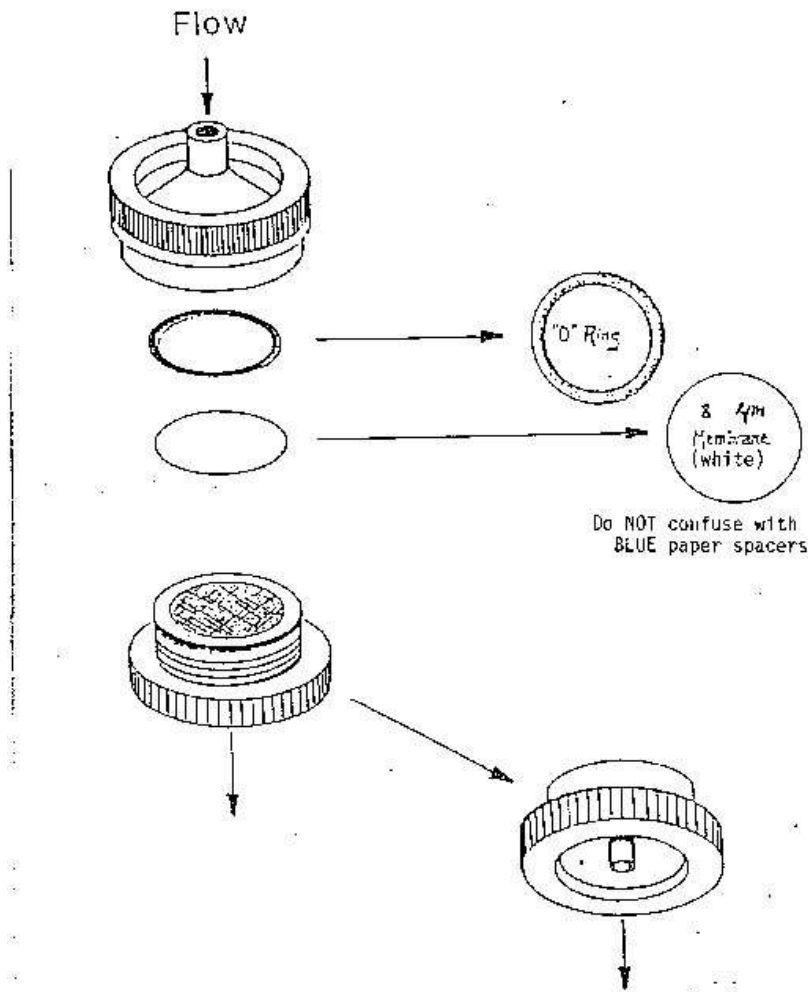
Microfilariae of:	<i>Dirofilaria immitis</i>	<i>Dipetalonema reconditum</i>
Numbers	May exceed $2 \times 10^4 \text{ ml}^{-1}$	Usually $< 10^3 \text{ ml}^{-1}$
Length	> 300 microns	< 300 microns
Width	6.7 - 6.9 microns	4.7 - 5.8 microns
Anterior End	slightly tapered (cone on a cylinder)	blunt (hemisphere on a cylinder)
Posterior End	straight (usually; may vary)	hooked (usually; may vary)

NOTE: As a further modification, a microfilaria count can be made if a measured amount of the stained mixture is counted. Although it is only a generality, *D. immitis* microfilaremias are often characterized by having high concentrations of microfilariae, whereas *D. reconditum* microfilariae are often found in low concentrations.

Filtration Method

1. Collect a 1 ml blood sample into EDTA or heparin and add to 10 ml lysing solution within a syringe. Mix thoroughly. (Lysing solution consists of 5.0 ml Triton X-100, 8.0 grams NaCO₃, 1 liter water.)
2. Attach syringe to a filter unit (see drawing). The lysed blood solution is pushed through an 8 μm pore filter membrane.
3. Remove the filter from the filter holder, place it on a microscope slide and add one drop of 1:10,000 Methylene Blue Stain. Cover filter with a cover glass and examine under microscope.

Millipore Filter Unit



C. Miscellaneous

It is frequently difficult to distinguish microfilariae of *D. immitis* from microfilariae of *D. reconditum* using the morphologic characteristics outlined above. More definitive techniques for differentiation are available, but they are not usually practical for routine use in the practitioner's laboratory.

The first technique employs a histochemical (acid phosphatase) stain of microfilariae. *D. immitis* stain positive in certain zones only and *D. reconditum* stain over the entire microfilariae. See *J. Am. Vet. Med. Assoc.* **158**:601-605, 1971 or consult a parasitologist.

The second technique exploits the fact that *D. reconditum* microfilariae have a cephalic hook and *D. immitis* microfilariae do not. Again, since this technique requires good microscopic capability, it may not be suited for routine use. See *Proc. Helminthol. Soc. Wash.* **32(1)**:15-20, 1965, or Bowman's Georgi's *Parasitology for Veterinarians* or consult a parasitologist.