

LABORATORY

4

Ascarids, *Oxyuris*, Trichocephalids

Introduction:

The ascarids are large parasitic nematodes that usually live in the small intestine of their host. All ascarids have 3 lips around the mouth opening and no buccal capsule. *Oxyuris equi* is a pinworm of horses and the female worms, as the common name suggests, have a long narrow tail. The pinworms live in the large intestine of their host. The Trichocephalids (the name describes the worm's shape: most have an anterior end that is narrower than the posterior) are some of the most important nematode parasites. All members of this group contain a structure call the "stichosome" that is part of the esophagus. The stichosome is composed of a long slender tube surrounded by a row of large cells (stichocytes).

Objectives:

The egg found in the feces is the usual diagnostic stage for the worms considered in this laboratory. Therefore, you should be able to identify the eggs of these worms. Sometimes you or your client will notice adult worms in feces or vomitus of infected animals and, therefore, you should also be able to identify the adults of these nematodes (most can easily be recognized by size and characteristic morphology). *Trichinella spiralis* is exceptional in that it does not have eggs or larvae occurring in the feces. For this species the L1 in the muscles is the diagnostic stage.

Checklist of Objectives

Be able to identify the following:

- The eggs of the following Ascarids: *Toxocara canis*, *T. cati*, *Toxascaris leonina*, *Ascaris suum*, *Parascaris equorum*. (Hint: knowing you have an ascarid egg and the host it came from, usually will identify the parasite, as most hosts only have one major ascarid parasite. An exception to this are dogs and cats, for which you will have to tell *Toxocara* eggs from those of *Toxascaris*.)
- Adult ascarids to species (except those of dogs and cats).
- The eggs of the following Trichocephalids: *Trichuris vulpis*, *Trichuris* spp. & *Capillaria* spp.
- The eggs and adult female of the horse pinworm: *Oxyuris equi*.
- Be able to identify the L1 of *Trichinella spiralis* in a "squash-prep" of muscle.

At the Bench

1.) Do a ZnSO₄ fecal centrifugation - flotation on the fecal samples under the hood. The following canine fecal samples are available:

Toxocara canis - Egg - (90 x 75 μm, pg. 21, Foreyt).

Using your 40 X objective focus carefully on the surface of the egg and note that the surface is pitted like a golf ball. At 10 X note that the egg is round and its contents almost fill the shell cavity.

Toxascaris leonina - Egg - (80 x 65 μm, pg. 21 & 55, Foreyt).

These eggs have a smooth shell (use 40 X objective). At 10 X note that the egg is slightly ovoid and the egg's contents do not fill the shell.

Trichuris vulpis - Egg - (80 x 40 μm, pg. 23, Foreyt).

Note the lemon-shape and the plugs at both ends. The egg is usually a light brown in color (or a dark brown when iodine is used). At 40 X note the smooth surface of the shell. All *Trichuris* eggs are similar to *T. vulpis*. Since a host usually has only one whipworm species that infects it, the identity of the egg can be determined by the host.

2.) The following slides are on each bench (one per bench):

Ascaris suum - Eggs - (60 x 45 μm, pg. 143 Foreyt).

Note: Some of the eggs have lost their rough proteinaceous outer layer. On a fecal float you may find some with the coat and some without, know them both ways.

Parascaris equorum - Eggs - (90 to 100 μm, pg. 129 Foreyt).

Note: many of the eggs have lost their rough proteinaceous outer layer. On a fecal float you may find some with the coat and some without, know them both ways.

Oxyuris equi - Eggs - (90 x 42 μm, pg. 127, Foreyt).

Note the operculum (cap) at one end. These eggs may be found in the feces, but since the female worm normally deposits them on the skin of the perianal area, scrapings of this region are more likely to reveal the infection.

3.) *Trichinella spiralis* - The causal agent of trichinosis. The migrating larvae (L1) cause the important pathology. The adult female gives birth to first-stage larvae, and, after migration these larvae encyst in the muscles, thus the L1 encysted in the muscle is the diagnostic stage.

“Squash prep” - take a **very** small (!!!) piece of muscle (from a rodent; center bench) and crush it between 2 slides and look for L1s using the 10 X objective. This is a diagnostic technique you can use in the field. It is easier to do this successfully with fresh tissue (i.e., before fixation).

4.) The following slides are in your student slide box:

A. *Trichinella spiralis* - Cross section of L1 in muscle: SSB#38 (pg. 188, Foreyt).

This is a specimen of encysted larvae as may be seen in histopathology. Note the nurse cell (the cleared muscle cell around the larva - the worm has rearranged the striated muscle cell to make it more accommodating).

B. *Ascaris suum* - Slide #SSB25 is a hematoxylin and eosin-stained section from the lung of a guinea pig, showing the damage due to migrating *Ascaris suum* larvae. The guinea pig had been experimentally infected 6 days previously. There is little histopathology associated with a primary infection; subsequent infections elicit a strong host response with marked cellular infiltration and granuloma formation around the killed larvae. A similar reaction in the liver produces "milk spots", the gross lesions visible on the liver's surface as white spots.

Demonstrations

Checklist Material:

- 1.) *Ascaris suum* - adults - this is the largest nematode of the pig, up to 40 cm long. The size of this worm, its location in the small intestine and the host are sufficient to identify it to species.
- 2.) *Ascaris suum* - eggs - Eggs - (60 x 45 μm , pg. 143 Foreyt). These ascarid eggs have a rough proteinaceous coat. Since *A. suum* is the only ascarid of pigs, knowing that this is an ascarid egg is enough to identify it to species.
- 3.) *Parascaris equorum* - adults - this is the largest nematode of the horse (up to 40 cm long), it is similar to *A. suum* in appearance. The size of this worm, its location in the small intestine and the host are sufficient to identify it to species. Given the size of this worm, they are occasionally noticed in the feces of infected animals, especially after the horse has been treated.
- 4.) *Parascaris equorum* - Eggs - (90 to 100 μm , pg. 129 Foreyt). These ascarid eggs have a rough proteinaceous coat which makes them sticky. Since *P. equorum* is the only ascarid of horses, knowing that this is an ascarid egg is enough to identify it to species.
- 5.) *Toxocara canis* - adult - This is a large (up to 18 cm) nematode of the small intestine of the dog. Adult worms from dogs may be confused with those of *Toxascaris leonina*. However, their eggs differ greatly and if eggs can be expressed from female adults a positive identification can be made. Males differ in the shape of the tail. Note the presence and shape of the cervical alae (clear cuticular flanges running along the anterior lateral margins of the worm). (See Diag. #1)
- 6.) *Toxocara canis* - Eggs - (90 x 75 μm , pg. 21, Foreyt) - Using the 40 X objective focus carefully on the surface of the egg and note that the surface is pitted (giving it the appearance of a miniature golf ball). At 10 X note that the egg is round and its contents almost fill the shell cavity. Unstained eggs are a light brown in color.
- 7.) *Toxascaris leonina* - adult - This ascarid is found in both dogs and cats. Grossly, the adults (up to 10 cm) are morphologically similar to those of the larger *Toxocara canis* in the dog, but are easily distinguished from *Toxocara cati* of cats by the shape of the cervical alae. In *T. leonina* the alae terminate gradually, merging into the cuticle, giving the anterior end of the worm a "lance-like" appearance (see Diag. #1) compared to the "arrow-head" appearance of *T. cati* (see below).
- 8.) *Toxascaris leonina* - Eggs - (80 x 65 μm , pg. 21 & 55, Foreyt). These eggs have a smooth shell (use 40 X objective). At 10 X note that the egg is slightly ovoid and the egg's contents do not fill the shell. Unstained eggs are clear in color.

9.) *Toxocara cati* - adults - The cervical alae of this worm (up to 10 cm) differ from those of *T. leonina*, the other ascarid of cats. The alae are broad and end abruptly, giving the anterior end an "arrow-head" appearance (see Diag. #1).

10.) *Toxocara cati* - Eggs - (75 X 65 μm , page 55 Foreyt). Other than being slightly smaller (a fact not noticeable unless you measure them) these eggs are identical to those of *T. canis*.

11.) *Trichuris vulpis* - Eggs - (80 x 40 μm , pg. 23, Foreyt). Note the lemon-shape (symmetrical, with the greatest width in the center) and the plugs at both ends. The egg is usually a light brown in color (or a dark brown when iodine is used). At 40 X note the smooth surface of the shell. All *Trichuris* spp. eggs are similar to *T. vulpis* (the size may vary slightly). Since a host usually has only one whipworm species that infects it, the identity of the egg can be determined by the host. In the United States cats are generally not infected by any whipworm. In rare cases a cat may have a transient infection with *T. vulpis* or if the cat has visited the islands of the Caribbean it may have *T. campanula*.

12.) *Capillaria* spp. - Eggs - (60 x 30 μm , pg. 57 Foreyt). There are many species capillarids and they are found in most vertebrates. The eggs resemble those of *Trichuris* (the whipworm), however, they are more cylindrical (the sides run parallel to each other, dipping in only at the plugs) than whipworm eggs and the plugs may appear to be asymmetrical with respect to the long axis of the egg. The unstained eggs are clear. The easiest way to distinguish these eggs from whipworm eggs is by the character of the surface: *Capillaria* eggs have a rough surface (either due to holes in or ridges on the shell) vs. the smooth surface of whipworm eggs - use the 40 X objective to see this.

The 2 important species seen in dogs and cats are:

Eucoleus (Capillaria) aerophila - a lungworm of foxes, dogs and cats. The adults are found embedded in the mucosa of the lungs.

Pearsonema (Capillaria) plica - these worms are found in the urinary bladder of foxes, cats and dogs, thus the eggs are found in the urine rather than the feces.

13.) *Oxyuris equi* - Eggs - (90 x 42 μm , pg. 127, Foreyt). Note the operculum (cap) at one end. These eggs may be found in the feces, but since the female worm normally deposits them on the skin of the perianal area, scrapings of this region are more likely to reveal the infection.

14.) *Oxyuris equi* - adult - The pinworms are found in the large intestines of their hosts. The name "pinworm" comes from the long pointed tail of the female nematode of some, but not all, species of this family. The female *O. equi* measures up to 10 cm long and has a long pointed tail. It is occasionally recovered from the feces. The males are less than 1 cm long and their tail is not unusually long, thus, they can be easily confused with small strongyles. They are found in the cecum, large intestine, and rectum of equids.

15.) *Trichinella spiralis* - Cross section of L1 in muscle - (pg. 188, Foreyt). This is a specimen of encysted larvae as may be seen in histopathology. Note the nurse cell (the cleared muscle cell around the larva - the worm has rearranged the striated muscle cell to make it more accommodating). You may see inflammatory cells around the larva during the acute phase of infection, but the inflammation resolves and is absent during the chronic phase.

Other related nematodes:

Ascaridoidea - The ascarids are large nematodes that usually live in the small intestine. All ascarids have three lips around the mouth opening and have no buccal capsule. Eggs are thick-shelled and unsegmented (one cell embryo) when passed. They embryonate in feces or fecally contaminated soil. Infection is by ingestion of the larvated (L2) egg, by ingestion of a larva in a paratenic host, or by vertical transmission (in utero or via the milk). Vertical transmission is particularly important among the ascarids of dogs (prenatal) and cats (transmammary).

1.) *Ascaris lumbricoides* - adult - This is the ascarid of humans. It is almost identical to *A. suum*. Humans may also occasionally be infected with *A. suum*.

2.) *Baylisascaris procyonis* - the ascarid of raccoons, causes an often fatal visceral larva migrans (cerebrospinal nematodiasis) in other animals, including humans and dogs. Some examples are: 1) Fatal CNS disease in a flock of 85 penned Bobwhite Quail. Soil analysis showed 10,000+ eggs in 1500 gm of soil from the floor of the pen, which had been previously used for raccoons. 2) A similar outbreak in a flock of 600 chickens raised on the ground was attributed to a wild raccoon. Its larvae also occur in man, in whom fatal infections have been reported. This parasite is receiving increasing attention in veterinary medicine and public health. This ascarid can infect dogs, although such infections may be rare. Its egg is similar to that of *Toxocara* spp. (pg. 188, Foreyt).

- a. Demonstration of Adults. Note the size of the adult worms. The adult worms lack cervical alae and are filled with thousands of eggs. If you should treat a "pet" raccoon, warn the client to dispose of the large, easily seen, adults (and the stools) by flushing them down the toilet. This applies to your premises also. Wash cages thoroughly with very hot water taking care that the wash water goes down the drain (steam clean if possible). Keeping raccoons as pets should be strongly discouraged.

3.) *Ascaridia galli* - The largest nematode of poultry. This worm lives in the lumen of the small intestine. (Size and predilection site are diagnostic.)

4.) *Heterakis gallinarum* - small nematode found in the large intestine and cecum of poultry. These occur in birds raised on the ground. They are one of the few parasitic nematodes known to be a **vector of another parasite**, the protozoan *Histomonas meleagridis*. (Size and predilection site are diagnostic.)

Generally speaking, the veterinarian, when working with poultry, is treating the flock, not individual birds. Therefore a diagnosis is normally made by necropsy of the culled sick birds and identification of the adult worms. Helminth parasites are increasingly important as poultry farming returns to nature ("organic") and birds are raised on the ground.

Trichuroidea - The common morphological feature of these worms is the presence of a "stichosome" which constitutes part of the esophagus. The stichosome is a structure composed of a long slender tube surrounded by a row of large cells (stichocytes).

5.) *Trichuris vulpis* -adult - The whipworm of the dog (*T. campanula* the cat whipworm, is very rare in the US). Adult worms are found in the cecum and large intestine, this nematode gets its common name from the long narrow anterior end and the shorter, thicker posterior end, both parts together give the worm the appearance of a whip. Disease is caused by the worms penetrating the epithelial cells of the cecum and colon with their narrow anterior end. When enough worms have accumulated, the damage becomes more than the dog can handle and clinical signs become evident.

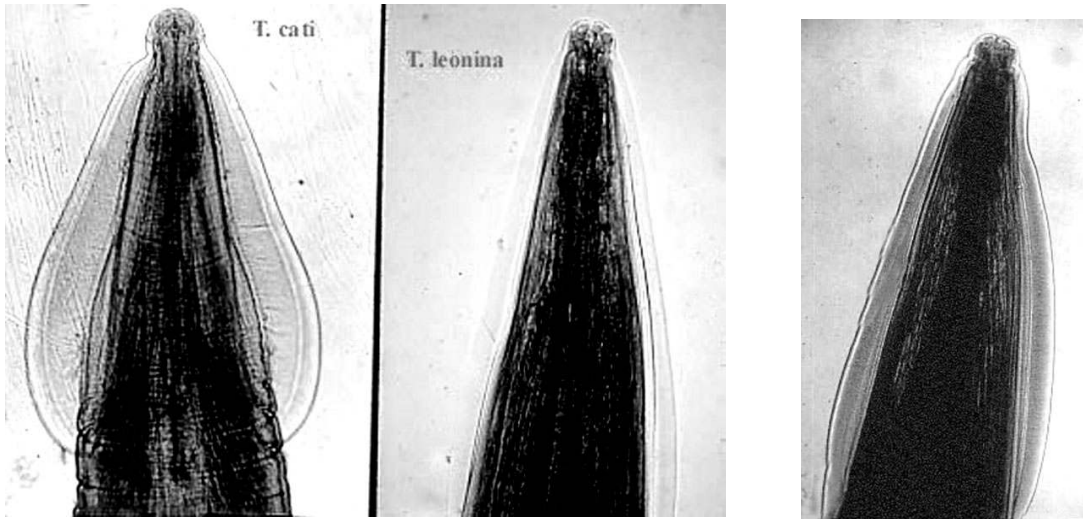
6.) *Trichuris* spp. - adult - Note the characteristic whip-like appearance. Whipworms are found in most mammals. In ruminants they generally do not cause disease. In pigs infected with both *Trichuris suis* and *Campylobacter jejuni*, there tends to be a more severe disease than when either pathogen is present alone.

Dioctophymatoideae - This family contains nematodes that infect birds and mammals. The males have one spicule and a muscular caudal sucker.

7.) *Dioctophyma renale* - the kidney worm. This is the largest nematode parasite of dogs (60 cm in length) and is found in the kidney (whose tissue it replaces). The host survives because only one kidney is infected. Eggs are found in the urine. *D. renale* is found in mammals that eat fresh water fish (the paratenic host). It is an occasional parasite of dogs, but an important parasite of minks and other animals farmed for fur. It has also been found in some seals.

Diagram #1.

The cervical alae of *Toxocara cati*, *T. canis*, and *Toxascaris leonina*. Note: *Baylisascaris procyonis*, a parasite of racoons which sometimes infects dogs, has no cervical alae.



Toxocara cati
alae wide at
base.

Toxascaris leonina
alae narrow at
base, identical to
Toxocara canis.

Toxocara canis
alae narrow at
base, identical to
Toxascaris leonina.