

LABORATORY

2

The Protozoa

Introduction:

The protozoa are unicellular animals that are classified on the basis of the organelles used for locomotion (flagella, pseudopodia, cilia or no observable organelle). They have a variety of life cycles reflecting the diverse nature of this phylum. The protozoa contain some of the most important parasites of animals.

Objectives:

In this laboratory, you will see many of the parasites that we have discussed in lecture. Some of these you will need to be able to identify because they are parasites commonly seen in practice. Others are shown to assist you in learning their life cycles.

Checklist of Objectives:

Learn to identify:

- | | |
|--|---|
| <input type="checkbox"/> <i>Giardia</i> cysts | <input type="checkbox"/> oocysts of <i>Cystoisospora</i> spp. (2 sizes) |
| <input type="checkbox"/> <i>Eimeria</i> oocysts | <input type="checkbox"/> <i>Cryptosporidium</i> oocysts (acid fast stained) |
| <input type="checkbox"/> <i>Toxoplasma</i> (cat) and <i>Neospora</i> (dog) oocysts | <input type="checkbox"/> sporocyst of <i>Sarcocystis</i> . |
| <input type="checkbox"/> <i>Giardia</i> trophozoites | <input type="checkbox"/> <i>Tritrichomonas</i> trophozoites |
| <input type="checkbox"/> <i>Babesia</i> spp. in a blood smear | <input type="checkbox"/> <i>Leucocytozoon</i> in a blood smear |

At the Bench

1. Schizonts and merozoites of *Eimeria tenella*. Wet prep: Scrape a small amount of material from the damaged mucosa of the chicken's cecum, place it on a slide with some saline and a coverslip. Look for the schizonts and merozoites. The merozoites will look like small banana shaped objects, while the schizonts will look like a round cell full of merozoites. The presence of these stages within a lesion of a bird's gut tells you that the bird is infected with *Eimeria*. The location of the lesion will tell you which species of *Eimeria* is causing the lesion.

2. Examine intestinal and cecal contents of a hamster for *Giardia* and *Trichomonas* trophozoites. Place a drop on a slide and cover with a coverslip. Do not add iodine as you want to see the movement of the trophozoites. Movies of these 2 parasites may be seen on your Course Materials web site under #4 Digital Media. *Giardia* trophozoites will be found in the hamster small intestinal contents. Look for the characteristic "Falling leaf motion" of the pear-shaped trophozoites (there will be some fast moving *Trichomonas* in this sample in addition to the less

highly motile *Giardia*). *Tritrichomonas muris* trophozoites will be found in the hamster cecal contents. At 40X and low light you should be able to see the undulating membrane as a flickering wave on the body of the trophozoite. These flagellates don't form cysts, so the diagnosis depends on identifying the trophozoite. Note how the movement of this organism differs from *Giardia*.

3. There are 3 fecal samples under the hood: *Giardia*, *Cystoisospora*, and *Eimeria*. Do a ZnSO₄ centrifuge flotation on each of these samples. Do this in teams and share your results with your bench mates. Please show the *Giardia* cysts to an instructor to be sure you are looking at the correct cysts (also, it helps to stain these cysts with iodine).

4. Make and stain a blood smear (see the instructions on pg Lab1, pg 16 and the video on the Course Materials web site) from the tube of mouse blood on the center bench (ask an instructor to remove the blood for you). The mouse was infected with *Babesia microti*. This small *Babesia* is similar in appearance to *B. gibsoni* which is found in dogs. *B. canis*, which is more common in dogs in our part of the country, would be larger in size (see the demonstration).

5. Examine the following slides from the Student slide box (some slides may be missing):

55 - *Balantidium coli* : This ciliate is a commensal of domestic animals (esp. swine). It can be pathogenic under some conditions. The trophozoite is found in the large intestine where it normally lives in the lumen, but it may invade the intestinal wall producing shallow ulcers.

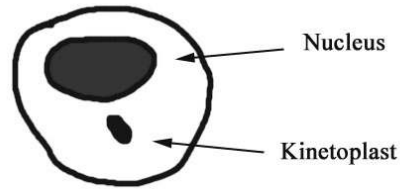
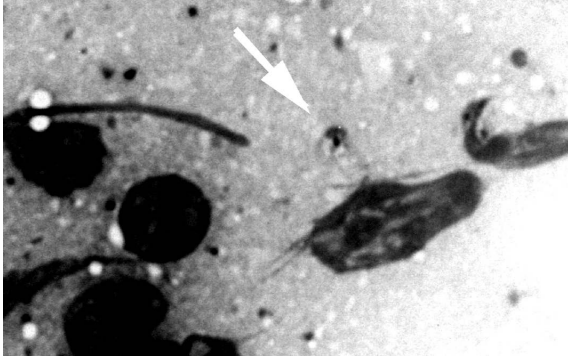
In Slide #55 trophozoites can be seen in the lumen of a hamster or horse large intestine, in the epithelium. A few are deeper into the tissue. Note the large macronucleus, visible in some of the trophozoites, and the cilia on all the organisms (use your 40 X objective and low light to see the cilia).

56 - *Balantidium coli* : In the stained fecal smear (SSB #56) note the cysts. They are spherical (40-60 µm) have a hyaline wall, and usually the large macronucleus can be seen within. Diagnosis is made by finding these large cysts in the feces.

39 - *Trypanosoma brucei* : Trypanosomes are extremely important parasites of domestic animals in Africa and South America. In North America, they are common parasites of birds, in which they may occasionally be pathogenic. *T. brucei* is used in this lab to show the typical morphology of the trypanosomes. This African flagellate is found in the blood and cerebrospinal fluid of mammals. Use your oil lens and observe the trypanosome with its undulating membrane, single anterior flagellum and kinetoplast.

41 - *Leishmania donovani* : *Leishmania* spp. are common parasites in tropical and sub-tropical areas of the world. They are found in rodents, dogs and humans. At VHUP, we have seen several cases of visceral leishmaniasis in dogs that were brought to this country from the Mediterranean region and the CDC is currently investigating infections in foxhound kennels in the eastern United States. This parasite exists as a flagellated promastigote in the gut of a sand fly or as a non-flagellated amastigote in the macrophages of a mammal. *L. donovani* is found in the

macrophages of the bone marrow, liver and spleen. Slide #41 (use your oil lens) is a spleen impression smear. This type of smear is made by cutting the organ and gently blotting on a paper towel to remove excess blood. The cut surface is then touched to a glass slide to leave the impression. The spleen cells rupture due to the excess surface tension and the cell nuclei and amastigotes are left behind. The cell nuclei stain as purple blobs and smears, while the amastigotes show up as small (2-3 μm) circles with a nucleus and kinetoplast.



Amastigote (arrow) in lymph node impression smear.

Drawing of an amastigote.

42 - *Tritrichomonas* spp.: Flagellates of this genus are found in the digestive tract or reproductive tract (*T. foetus*) of mammals and birds. In most cases, *Tritrichomonas* spp. are normal inhabitants of the digestive tract (esp. the cecum) and are generally considered non-pathogenic. There have been reports of diarrhea in which large numbers of *Tritrichomonas* sp. have been seen, but these reports haven't shown that these flagellates were responsible for the condition. *T. foetus* is the only proven pathogen of veterinary importance and will infect cattle (reproductive tract) and cats (GI tract).

54 - *Babesia canis* : This small protozoan is found in the red blood cells of dogs and is transmitted by ticks. (It is more often seen in blood obtained from cutaneous capillaries than from systemic venous blood, however, the diagnosis is usually based on having an antibody titer to the organism.) They may be round or pear-shaped, 2-5 μm long (a red cell is 7 to 10 μm) and several may be seen in the same red blood cell. Use your oil lens to see these organisms. (**Foreyt, pg. 44**)

47- *Eimeria* spp. : These are common parasites of the GI tract of birds and herbivores. They also are very host specific (most *Eimeria* species are able to infect only one species of host). *Eimeria tenella* causes cecal coccidiosis of chickens. SSB #47 is a cross-section of the cecum of an infected chicken. Second generation schizonts (day 5 of infection), each containing many merozoites, can be seen in the sub mucosa. There is hemorrhage in the sub mucosa. The cecal content is primarily blood. In this blood you may see schizonts and sloughed epithelial cells.

50 - *Sarcocystis* spp.: This parasite has a herbivore - carnivore life cycle, for example, *Sarcocystis cruzi* has a dog-cattle cycle. This slide is a section of infected muscle from the cow intermediate host.. Note the large sarcocysts which contain many banana-shaped **bradyzoites**. The dog is the definitive host. When the dog eats raw infected muscle the parasite invades and multiplies in the

lamina propria of the small intestine. Oocysts sporulate rapidly in the intestine and generally the delicate oocyst wall ruptures while still in the intestine, thus **sporocysts** are passed in the feces.

97 - *Cryptosporidium* sp.: This slide is an acid fast stain of a direct fecal smear of from a calf. At 40X, you will see the oocysts as small, round red dots. The diagnostic stage is the small (4 μm) round oocyst containing 4 sporozoites. The size and shape of the oocyst are the same as those of yeast which may also be found in normal or diarrhetic stools. In order to positively identify these oocysts, a special staining technique has been devised. It was found that, like tuberculosis bacteria, these oocysts are acid-fast when stained with an acid-fast stain. That is, they will appear red after staining, while yeast (not acid- fast) will appear blue-green. Note that these oocysts have a lighter staining area in the center, in unstained oocysts that one might find on a fecal float, this area would appear highly refractile, giving the small spheres the appearance of having a hole in the center. Since both oocysts and yeast will float in a fecal float, the presence of small, round organisms in a fecal float would call for the acid-fast stain to confirm the diagnosis.

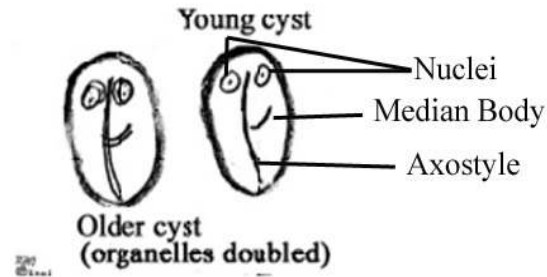
This coccidian can infect a large number of different hosts including both mammals and birds. Since the same species infects both domestic animals and man, this organism is a public health hazard (this was discovered when a large portion of a veterinary class at Auburn came down with cryptosporidiosis after examining a calf with “scours”).

Demonstrations

Checklist Material:

1. **Giardia cysts.** The cysts are small (10-15 μm - just visible at 10X), oval in shape, and contain remnants of the trophozoite organelles (usually the remains of the axostyle can be seen cutting across the long axis of the cyst, and the nuclei are at one end - see the figure below). It is much easier to see the internal details of these cysts if the material is stained with iodine and examined using the 40X objective. Since the plane of view at 40X is very narrow it sometimes helps to focus up and down on the cyst. This will bring the whole length of the axostyle into view allowing for a definitive identification.

This flagellate is an inhabitant of the small intestine of mammals and birds. The cyst stage is usually found in the feces of infected animals, but in diarrhetic stools the trophozoites can sometimes be seen. Since trophozoites will be destroyed by the high salt concentration of a fecal float you must examine liquid stools for the trophozoites by making a thin direct smear and looking for the characteristic movement of these trophozoites (you can try this with the material in MDL-11). These cysts will float in standard salt solutions, but the highly concentrated salt solutions cause osmotic damage to the contents of the cysts. Therefore, a ZnSO_4 solution (which is not saturated, thus, less osmotically damaging) and centrifugation (to reduce the amount of time the cyst is in the salt solution) is used for flotation. Adding iodine to the material recovered from the float will not only stain the internal structures, it also dilutes out the salt solution giving you more time to examine the material. (**Foreyt, pg. 35**)

Drawings of *Giardia* cysts

2. ***Tritrichomonas* trophozoites.** Other than the many flagella emerging from the cell, there isn't much to see in this stained preparation. The undulating membrane might be recognizable as a wavy line along one side of some the trophozoites, but it is much easier to see when the trophozoite is alive and moving (you can try this with the material in MDL-11). Like *Giardia* trophozoites, these will be destroyed by the high salt concentration of a fecal float and therefore you must examine liquid stools for the trophozoites by making a thin direct smear and looking for the characteristic movement of these trophozoites. Unlike *Giardia* these parasites do not have a cyst stage so you will rarely find them in formed stool. In cattle they live in the reproductive tract of the cow and on the penis of the bull. To diagnosis the infection you must swab the prepuce of the bull and either examine a smear made from the swab (mixing it with a small amount of saline to keep the trophozoites alive) or culture the swab in growth medium and look for the trophozoites after they have multiplied for a few days. In cats, you can either look at a direct smear of diarrhea for trophozoites or culture the feces in growth medium. The results of culturing can be seen in the demonstration on the second microscope.

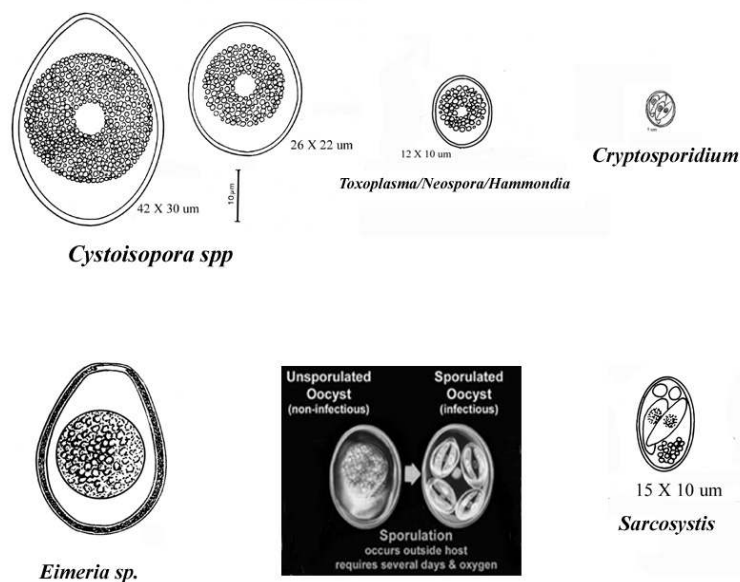
3. ***Babesia* trophozoites.** As you saw in slide 54 from your slide box, these parasites live within red blood cells and are thus very small. They are pyriform (pear-shaped) and generally only one or two will be seen within a RBC. The infected cells tend to be "sticky" and will accumulate within capillaries, thus it is more likely to diagnosis an infection if you make a blood smear from a skin prick, then from blood drawn from a vein. The infected cells tend to be larger than normal RBC and thus will accumulate with the WBC when blood is spun, thus a smear of the buffy coat will be more likely to yield a positive result. Even in heavy infections the percentage of infected cells will be very low, so you must examine many fields using your oil immersion lens to have any chance of finding the parasite. Generally, if an examination of a smear is negative in a dog showing symptoms of babesiosis, you would send out for an antibody titer.

4. ***Leucocytozoon* gametocytes.** Schizogony occurs in the tissues and gametocytes are found in blood cells (usually the white cells) of birds. They distort the host cell and appear more spindle shaped than oval. Two species (*L. smithi* and *L. simondi*, in turkeys and ducks, respectively) are pathogens, but other non-pathogenic species are common in birds. (Foreyt, pg. 162)
[Remember that avian erythrocytes are nucleated.]

5. **Coccidian oocysts.** The diagnostic stage of this group of parasites is the oocyst which is passed in the feces. One type of oocyst has 2 sporocysts, each containing 4 sporozoites (this type is seen in *Cystoisospora*, *Sarcocystis*, and *Toxoplasma*). A second type of oocyst contains 4 sporocysts, each with 2 sporozoites (this type is seen in the genus *Eimeria*). In some genera (e.g. *Cryptosporidium*) the oocyst contains only sporozoites (no sporocysts).

Depending on the species, the oocyst may be passed unsporulated and require development in the environment before it is infective, or may be passed in a sporulated form and be immediately infective. Note that the older literature refers to *Cystoisospora* as *Isospora*.

The coccidian oocysts are generally small (4 to 40 μm), round to egg-shaped, with clear walls (although some of the oocysts of *Eimeria* may have a yellow or pink tinge) and have a single undivided embryo in them when first passed in the feces. The following demonstrations are set up in order by size of the oocyst. Since a single host may have one or more of these parasites, and many of the oocysts have the same shape, being able to judge the size of the oocysts is very important in the identification of these parasites. The oocysts are easily recovered from feces by the ZnSO_4 centrifugational flotation technique.



A. *Cryptosporidium sp.* Note that these oocysts (which are immediately infective for the next host and each contain 4 sporozoites) are very small (4 - 5 μm) and thus they are difficult to tell apart from yeast. Therefore, the acid fast staining technique is used to stain these oocysts red (acid fast), yeast is not acid fast and therefore would appear green or blue with this staining technique. Most mammals can be infected with this parasite.

B. *Toxoplasma gondii*, *Neospora caninum*, and *Hammondia spp.* (Foreyt, pg. 52, 60)

The diagnostic stage of a *T. gondii* infection in a cat is the oocyst. Oocysts are small (10-12 μm) and round, and they are **identical** to those of *Neospora caninum* and *Hammondia spp.* Knowing the host will allow you to rule out one of these 3 parasites as *T. gondii* oocysts are only shed by cats and *N. caninum* oocysts are only shed by dogs. However, some species of *Hammondia* will infect dogs and some will infect cats, thus finding a small 10 μm oocyst in the feces will only allow you to say the dog is infected with *Neospora* **or** *Hammondia*, or the cat is infected with *Toxoplasma* **or** *Hammondia*. A definitive diagnosis may be arrived at by following up a positive fecal exam with a serological test for antibodies to *Toxoplasma* or *Hammondia*, but remember a negative test does not rule out anything. A positive serology for IgM along with

oocysts in the feces would be a definitive diagnosis. A positive serology for only IgG would be suggestive, but may also mean that the animal has been previously infected with the parasite being tested for and is now infected with *Hammondia*. Since *Hammondia* is rarely a pathogen in dogs or cats there is no available serology test. Experimentally, PCR has been used to separate these three parasites.

Oocysts of *T. gondii* are shed for only 1 or 2 weeks during the first infection (usually in young cats) and the cat is then immune to re-infection. Older cats whose immune system is compromised may also shed oocysts. Unsporulated oocysts need 48 hrs to sporulate. Dogs may be infected with the tissue cysts of either *Toxoplasma* or *Neospora*, in which case there may be disease (during the acute phase of the infection) but no oocysts in the feces. In this case the diagnosis would depend on linking the clinical signs with a positive serology.

C. *Cystoisospora* (syn. *Isospora*) spp. - (Foreyt, pg. 35, 61)

Parasites of this genus occur in carnivores and omnivores and are very host species specific. This protozoan is an intra-cellular parasite of the epithelial cells of the small intestine. Most species are not highly pathogenic and dogs and cats usually harbor several different species which will differ in size of the oocysts. For example in the dog, *C. canis* measures about 40 µm long while *C. ohioensis* will measure about 20 µm. *I. suis*, a common parasite of pigs, is an example of a pathogenic species. Oocysts, the diagnostic stage, are passed unsporulated and take 24 to 48 hours to sporulate and reach infectivity. Oocysts found in the dog and cat range from 12 to 40 µm long. Sporulated oocysts of *Cystoisospora* sp. will contain 2 sporocysts (easily seen) each with 4 sporozoites (not easily seen at 40X).

D. *Eimeria* spp. - (Foreyt, pg 93)

Parasites of this genus occur in herbivores and omnivores and are very host species specific. Oocysts range from 11 to 80 µm long. Sporulated oocysts of *Eimeria* sp. will contain 4 sporocysts (easily seen) each with 2 sporozoites (not easily seen at 40X). Some of the oocysts of *Eimeria* will have a structure known as a micropyle (a thinning of the oocyst wall), which is never found in oocysts of *Cystoisospora*.

E. *Sarcocystis* spp. - (Foreyt, pg 35)

Parasites of this genus occur in carnivores (definitive hosts) and herbivores (intermediate hosts). The oocysts produced in the intestine of the carnivore definitive host will sporulate immediately (in the host's intestine) and the fragile oocyst wall will usually rupture (again while still in the host), thus the diagnostic stage is the **sporocyst** (containing 4 sporozoites). Members of this genus are generally non-pathogenic in the definitive host, but highly pathogenic to the intermediate host.

Other protozoan parasites:

Ciliophora - The ciliates:

Balantidium coli (see page 10-2).

Sarcomastigophora - The amoebae and flagellates:

Entamoeba histolytica.

This amoeba is one of the few pathogenic amoebae of veterinary importance. It is

primarily a parasite of humans and primates, but can occasionally infect other hosts such as the dog. However, cysts are only passed in the feces of humans and primates, so they are the source of infection for domestic animals. Note the characteristic nucleus in the trophozoite. The trophozoite will have 1 nucleus and a feeding vacuole which may contain red blood cells.

E. histolytica presents a diagnostic problem in dogs as only the trophozoite will be passed in the feces. Since a salt float would destroy this stage the only way to see them is to do a direct smear (staining the smear greatly improves your chances of identifying the amoeba).

Histomonas meleagridis - (see slide and specimen in pathology section of Demonstrations)

This flagellate is pleomorphic, appearing as a flagellated cell in the lumen of the cecum and as an amoeboid cell within the tissues of the cecal wall and liver. It is the cause of “blackhead” in turkeys, game birds and peafowl. It may infect chickens but the disease is less severe in these birds. It has no cyst stage and is passed bird to bird in the eggs of the cecal worm *Heterakis gallinarum*. The livers of infected birds will have large white to yellow crater-like lesions on the surface of the liver and the lumen of the ceca can become packed with caseated plugs. The birds generally will have a yellowish diarrhea. A diagnosis can be confirmed by finding the organisms in a scraping of the cecal wall.

Trypanosoma brucei - (see pg 10-2)

Leishmania donovani - (see pg 10-2 and 10-3)

Apicomplexa - The Piroplasma, Haemosporidia, and coccidia.

The Piroplasma:

Babesia canis - (see pg 10-3)

The Haemosporidia:

Hemoproteus sp. - Members of this genus are very common in birds and can also be found in reptiles. Schizogony occurs in the tissues and gametocytes are the only stage found in the red blood cells of birds. *Hemoproteus* spp. are generally considered non-pathogenic and are transmitted by blood sucking flies.

The Coccidia:

Eimeria spp. - (see slides and specimen in pathology section of Demonstrations)

Sarcocystis spp. - (see specimen in pathology section of Demonstrations)

Toxoplasma gondii - (see slide in pathology section of Demonstrations)

T. gondii has a cat - mammal/bird cycle, with the intestinal infection occurring only in the definitive host, the cat. Any of a number of mammals or birds on which cats prey may act as non-obligatory intermediate hosts. Other mammals, such as man and dogs, can be infected with the asexual stages of *T. gondii* but are **dead end hosts** (i.e., they are not eaten by the cat).